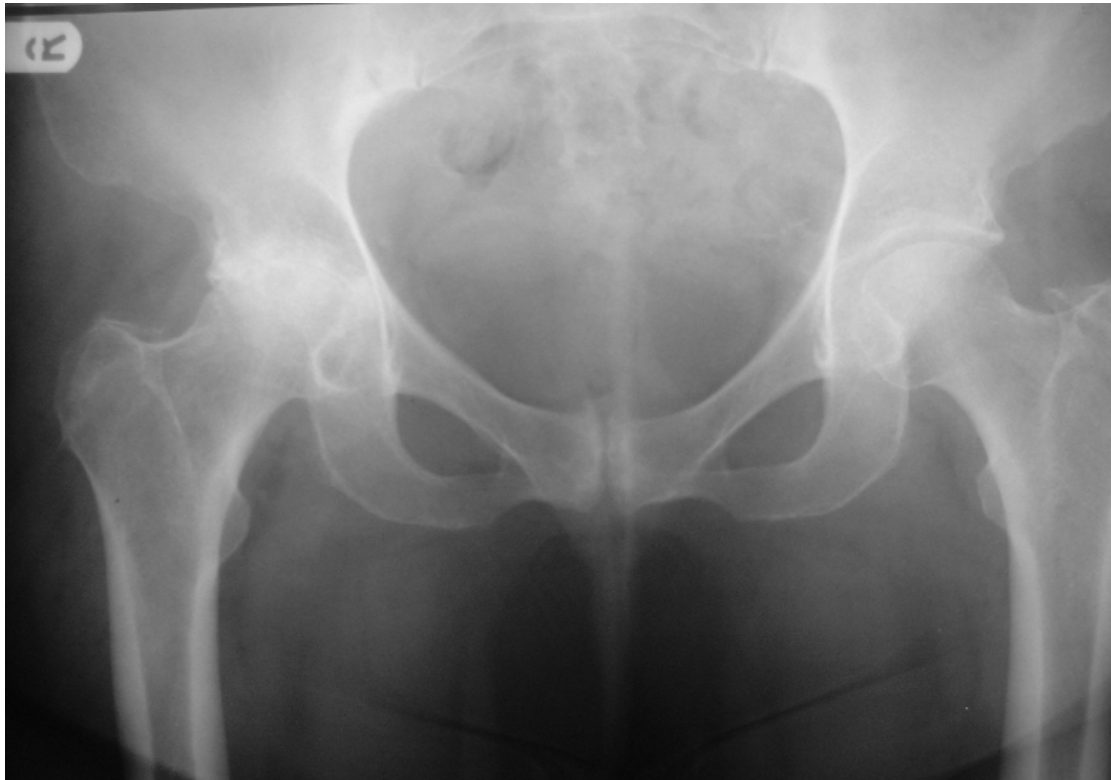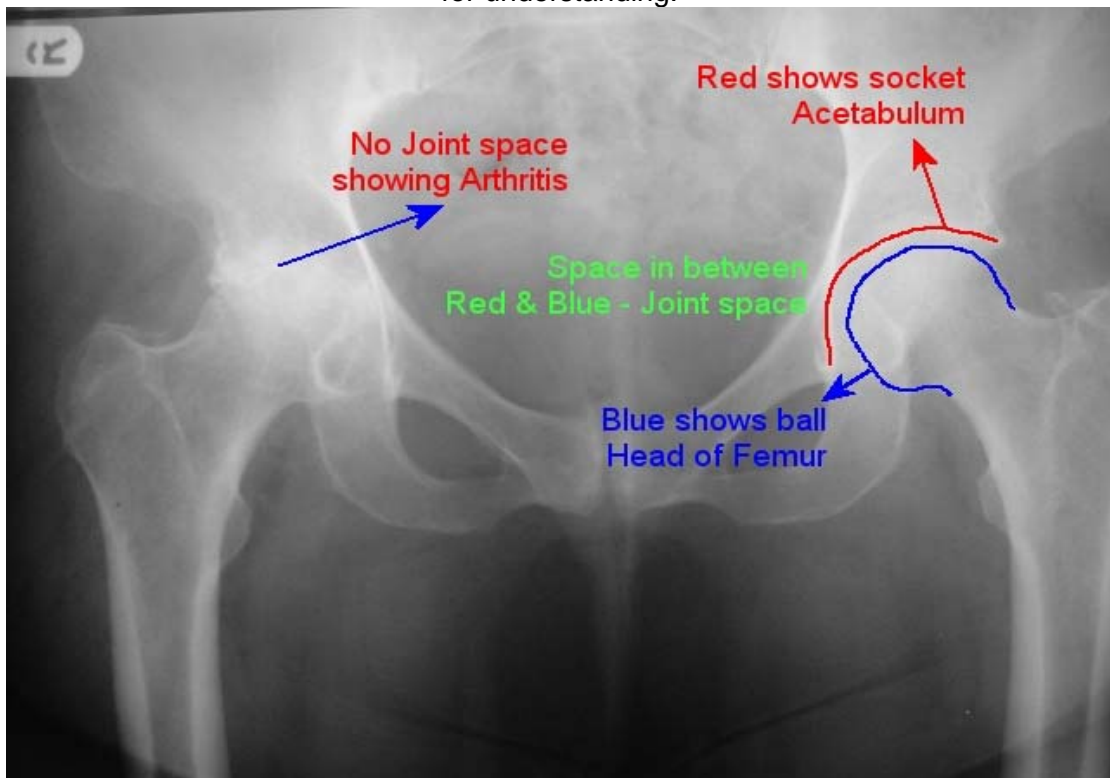


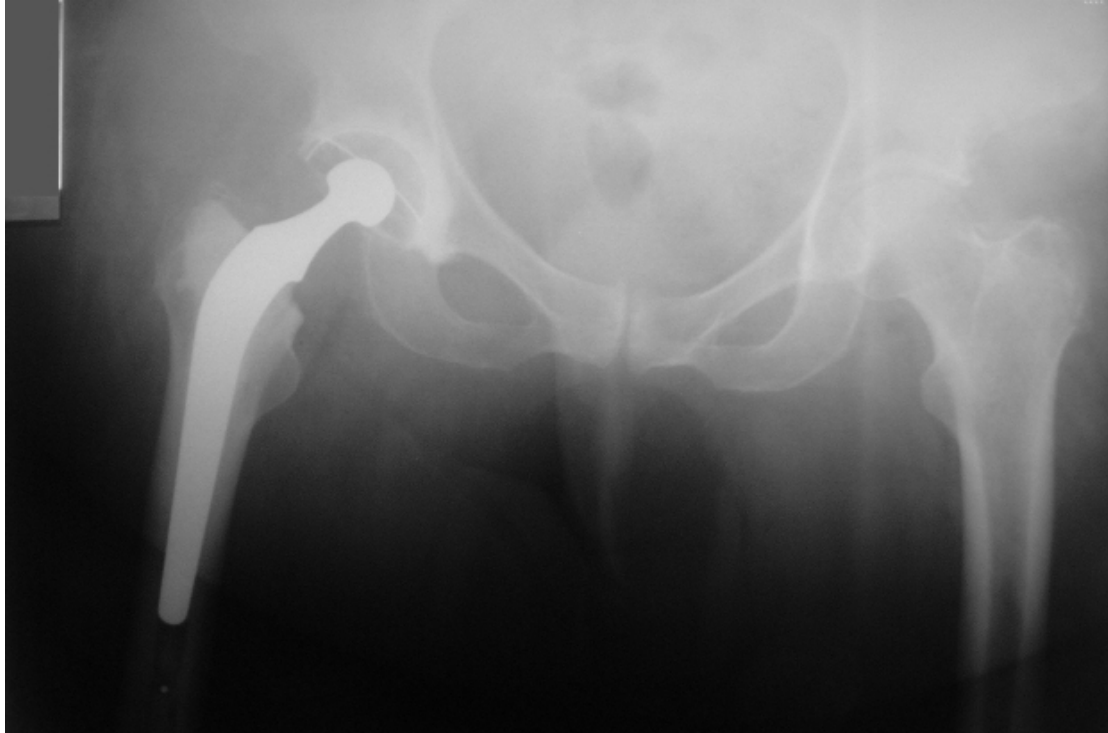
Arthritis of the Hip



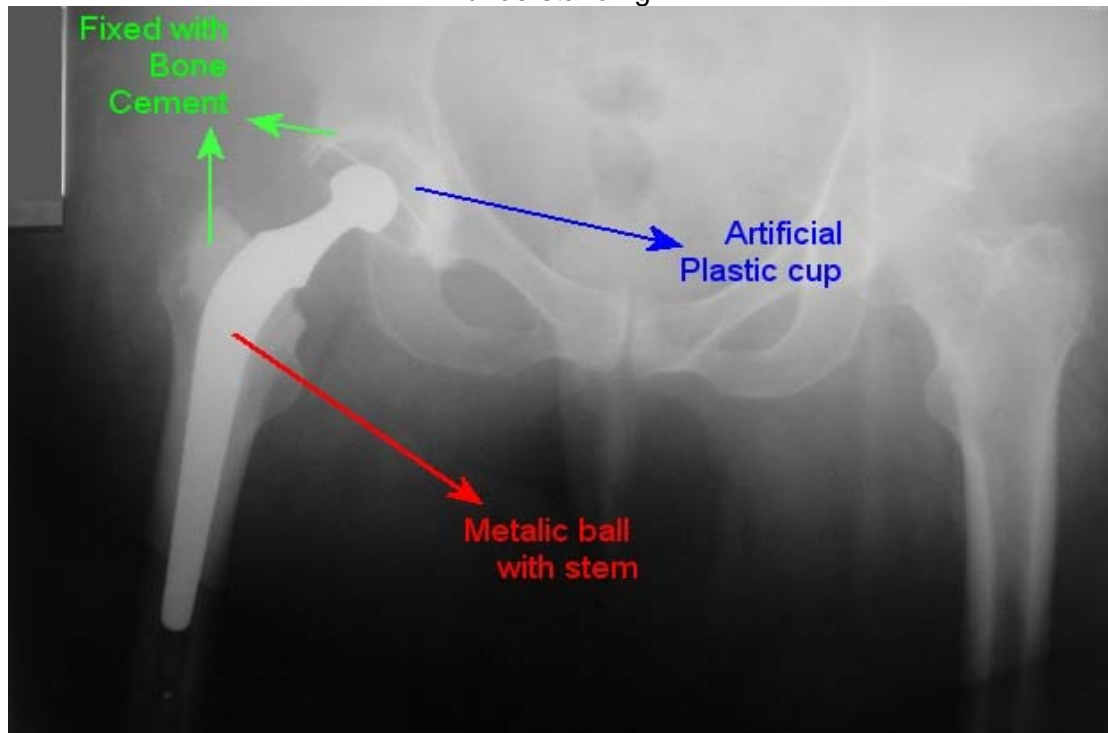
X-ray of pelvis showing Arthritis in the right hip and normal hip on the left. Both images (above and below) are the same. The image on the bottom has been labelled for understanding.



Cemented Total Hip Replacement



X-ray of pelvis showing an artificial cemented hip on the right. Both images (above and below) are the same. The image on the bottom has been labelled for understanding.



If you have any questions or queries please do not hesitate to contact.

Mr. George Ampat

Consultant, Trauma, Orthopaedics, Joint Replacement and Spinal Surgery

Southport District General Hospital,

Town Lane, Southport, PR8 6PN

Tel Secretary 01704704192

E-mail: geampat@gmail.com

Capio Renacres Hospital,

Renacres Lane, Halsall, Nr. Ormskirk,

Lancashire L39 8SE

Tel +44 (0) 1704 841133 Fax +44 (0) 1704842030