

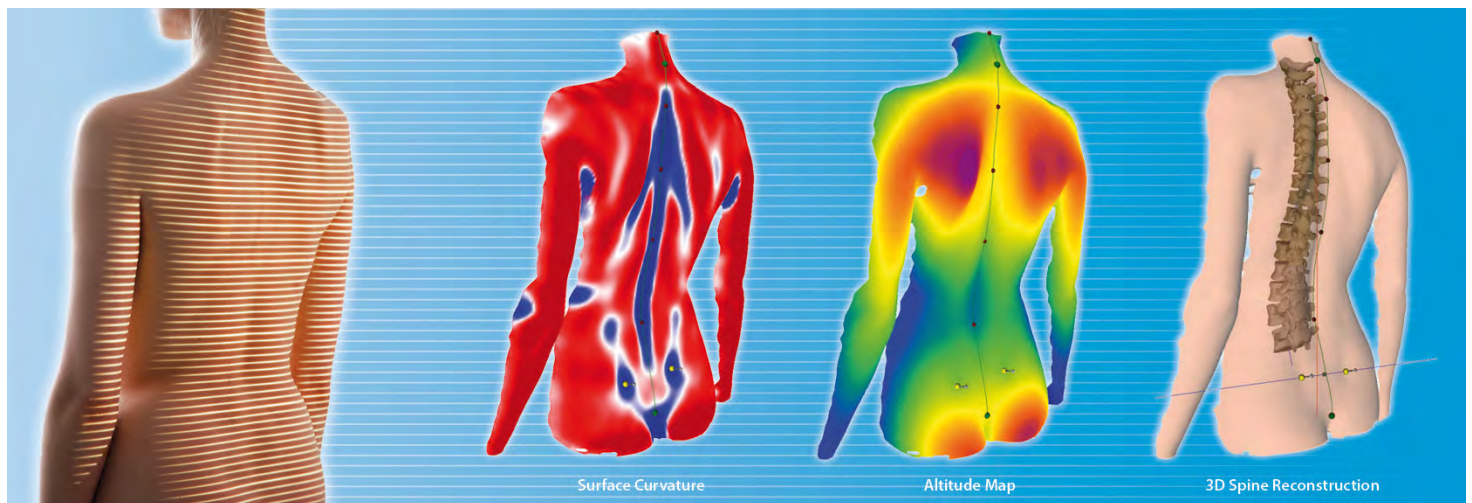
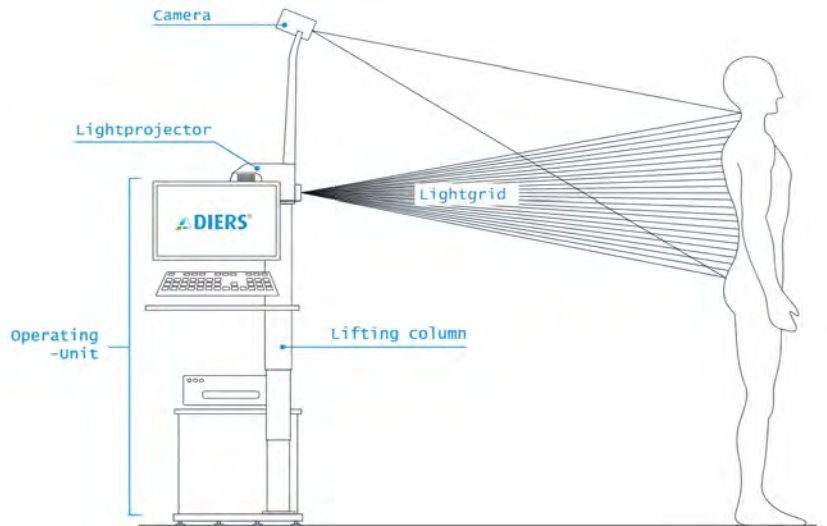
# Formetric 4-D Surface Spine Scan Rasterstereogram

## Imaging / Investigating Low Back Pain

There are many methods to image the spine. X-rays, MRI scans, CT scans, Bone Scans and Rasterstereograms are some of the methods. X-rays are good to identify fractures and deformities. MRI scan is most useful if there is neurological deficit (weakness of muscle, numbness of sensation etc.). CT scan are mostly used to assess the stability of the spine following fractures. Bone scans are useful to identify cancer or infection in the spine. Surface topography (Rasterstereogram) is another method of imaging the spine without the use of X-rays. It was initially used for scoliosis but is increasingly being used for mechanical back pain.

## Risks of using X-rays

Though X-rays is one of the best methods for analyzing spinal deformities like scoliosis it has serious side effects. X-rays use ionizing radiation and hence can cause significant increase in the risk of cancer later in life. The relative risk of breast cancer, for example, is nearly 4 times greater in a patient with Scoliosis who has had X-rays to monitor their deformity. X-rays also should not be performed in mechanical low back pain unless there are red flags.



## Rasterstereogram - How is it Done

The rasterstereogram is performed by projecting stripes of white light (raster lines) onto the back of a standing / walking patient. Then multiple digital images are captured to assess pinpoint surface asymmetry and identify bony landmarks. The system then compares the observed surface topography to a database of thousands of radiographic and topographic measurements of patients, utilizing a complex algorithm to quickly re-create a three dimensional representation of the patient's spine without exposing them to harmful radiation. This method has been successfully been used in monitoring patients with scoliosis.

**FEET AND SPINE**  
*Shoes, supports & seats*

Units 4 & 5, (beside Monkhouse), The Precinct, Cheadle Hulme SK8 5BB.  
Tel 01614884491 [www.feetandspine.com](http://www.feetandspine.com) [info@feetandspine.com](mailto:info@feetandspine.com)

# Formetric 4-D Surface Spine Scan - Rasterstereogram

## Mechanical Back Pain requires a Mechanical investigation and potentially a Mechanical solution

### MRI scans for Mechanical Back Pain is unnecessary

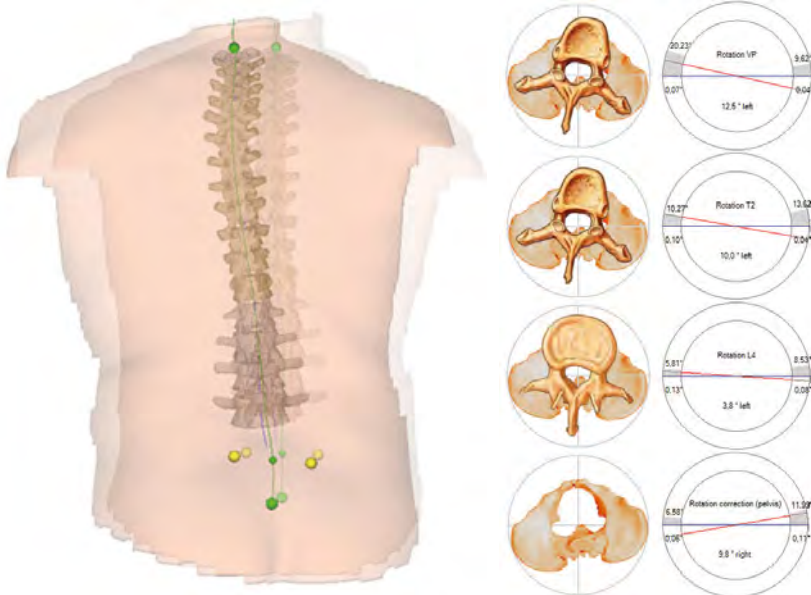Unfortunately MRI scans are increasingly being used for Mechanical Back Pain. MRI scans for mechanical low back pain is unnecessary and does not aid in providing a solution. A recent study from the University of Massachusetts-Lowell showed that MRI scans without clear indications led to potentially unnecessary services including surgery.

Ref: The cascade of medical services and associated longitudinal costs due to nonadherent magnetic resonance imaging for low back pain. Webster BS, Choi Y, Bauer AZ, Cifuentes M, Pransky G. Spine (Phila Pa 1976). 2014 Aug 1;39(17):1433-40.

### Rasterstereogram and Mechanical Back Pain

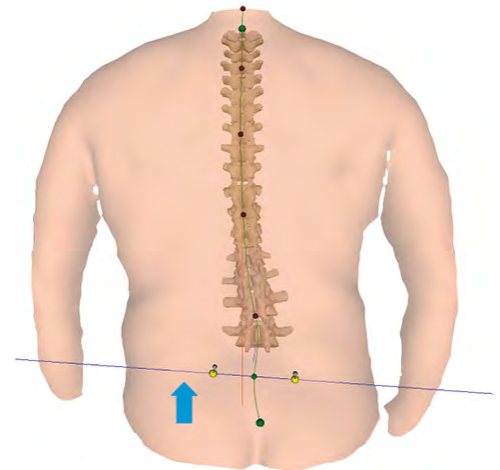
Emerging evidence suggests that alterations in the shape of the the spine is the cause of mechanical low back pain.

Spinal Alignment and Low Back Pain Indicating Spine Shape Parameters by Schroeder Jan and Mattes Klaus. Chapter 1 in Low Back Pain Pathogenesis and Treatment Edited by Yoshihito Sakai, ISBN 978-953-51-0338-7, 256 pages, Publisher: InTech



Example 2 - Patient with mid back pain has increased thoracic spinal rotation indentified on Rasterstereogram. Solution - An exercise programme for muscle re-education and an ergonomic chair.

**Disclaimer - Please note that Mechanical Back Pain is complex and we cannot find answers and solutions for all cases. Our intention is to find simple mechanical solutions that may help alleviate disabling mechanical back pain.**



Example 1 - Patient with low back pain and leg leg discrepancy - identified by Rasterstereography. Solution - A heel raise costing a few pounds.

A recent research study from the National University in Cheon-An City, Korea has demonstrated how rasterstereogram has been used to investigate and treat sacro iliac joint dysfunction.

Ref: The effect of sacroiliac joint mobilization on pelvic deformation and the static balance ability of female university students with SI joint dysfunction.

Son JH, Park GD, Park HS. J Phys Ther Sci. 2014 Jun;26(6):845-8